



PATIENT

Jesse Henderson

SPECIES

Feline

BREED

DSH

SEX

Female Spayed

AGE

12 years

WEIGHT

9.6lbs

INTERPRETED BY

Maggie Machen Lamy,
DVM, DACVIM
(Cardiology)

IMAGING PERFORMED BY

Kelly Vazquez, CVT

PRESENTING CLINICAL SIGNS

History: Grade 1/6 heart murmur auscultated during routine exam. Owner reports intermittent periods of open mouth breathing.

ECHOCARDIOGRAM FINDINGS

2D, m-mode, color flow and doppler imaging is available. The left ventricular wall thickness is normal. There is a mildly hyperechoic endocardium with regions of irregularity. The left ventricular chamber is normal in dimension. The papillary muscles appear normal. The left atrium is normal in size. The right atrium is normal in size. The right ventricle appears normal. The mitral valve is normal in structure and mobility. There is trivial mitral regurgitation present. Mild tricuspid regurgitation identified. Normal TR velocity. Blood flow through both the LVOT and RVOT are normal in velocity. No effusions or cardiac tumors are identified.

CARDIAC CHART

FELINE CARDIAC PARAMETERS	BODY WEIGHT (kg)	HR (BPM)	IVSd (cm) <small>(Moise, Pipers)</small>	LVIDd (cm) <small>(Moise, Pipers)</small>	LWVd (cm) <small>(Moise, Pipers)</small>	FS (%)	EF (%)
NORMAL PARAMETER	-----	150-240	0.35-0.55	<2 (mean 1.5)	3.5-0.55	35-67	80-100
PATIENT	4.4	125	0.45	1.1	0.41	58	90
FELINE CARDIAC PARAMETERS	LA/AO (Boon)	LA/AO HEART BASE (Swe) (Abbott)	LA 2D short axis Base view (cm) (Abbott)		LVOT VEL (m/s)	RVOT VEL (m/s)	E max (m/s)
NORMAL	<1.5	<1.3	<1.2		<1.6	<1.3	<0.9
PATIENT	1.3	1.0	1.0		0.7	0.8	NM
<p><i>*Note: All measurements based upon multi-modal images and methods. An average value is reported.</i> Adapted from June Boon, Veterinary Echocardiography, 1998 Abbott J & MacLean H JVIM 2006;20: 111-119, Moise et al. Am J Vet Res 47:1476, 1986. Pipers et al. Am J Vet Res 40:882, 1979.</p>							

INTERPRETATION OF THE FINDINGS & FURTHER RECOMMENDATIONS

The only abnormality identified is mild tricuspid regurgitation. TR in cats is most often physiologic, with little progression or clinical relevance. The left heart is largely normal with mild remodeling and fibrosis, which is likely an age-related variant. Both atria are normal, indicating low risk for complication. No additional issues are noted.

No cardiac contributing to intermittent open mouth breathing is suspected. Consider primary respiratory disease.

No cardiac contraindication for anesthesia at this time.

No medications are indicated. Monitor in the future for respiratory compromise, syncope/lethargy, or signs of a blood clot (paralysis, lameness).

Recommend recheck echocardiogram in 12 months to screen for progression.

INVOICE

29189

DATE

2/22/23

HOSPITAL NAME

Animal General on Hudson

REFERRING VET

Dr. Lang



PATIENT

Jesse Henderson

SPECIES

Feline

BREED

DSH

SEX

Female Spayed

AGE

12 years

WEIGHT

9.6lbs

INTERPRETED BY

Maggie Machen Lamy,
DVM, DACVIM
(Cardiology)

**IMAGING
PERFORMED BY**

Kelly Vazquez, CVT

HOSPITAL NAME

Animal General on
Hudson

REFERRING VET

Dr. Lang

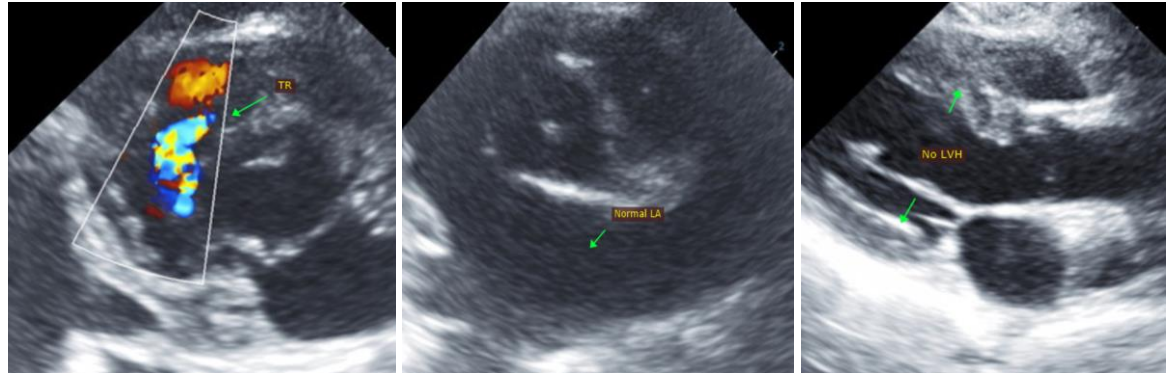
INVOICE

29189

DATE

2/22/23

IMAGES



The information and recommendations provided are based on the images presented by the referring veterinarian. No evaluation can be communicated regarding pathology that was not visible in the image/video clips provided.

Thank you for this referral. This report was generated using transcription software, and minor dictation errors may be present. If the clinical or image interpretation does not parallel your findings or if I can be of any further assistance, please contact me.

Maggie Machen Lamy, DVM
Diplomate of the American College of Veterinary Internal Medicine (Cardiology)
info@sonopath.com